

IVORY Graft

Case Report

Patient: Male patient 79 year old

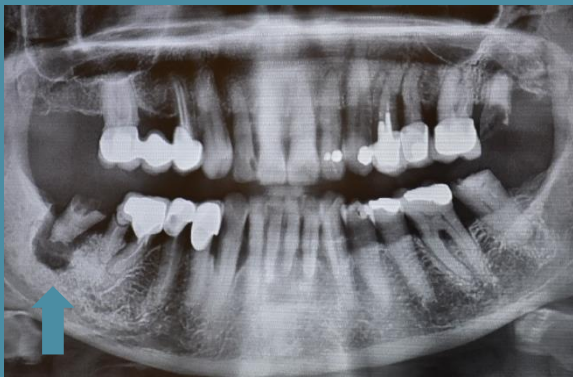Medical condition: Had vast alveolar bone and mandibular lingual plate destruction. Came for Extraction (and augmentation) of tooth 47.

Graft: Ivory's Dentin Bone Graft (from a syringe), mixed with patient's own blood

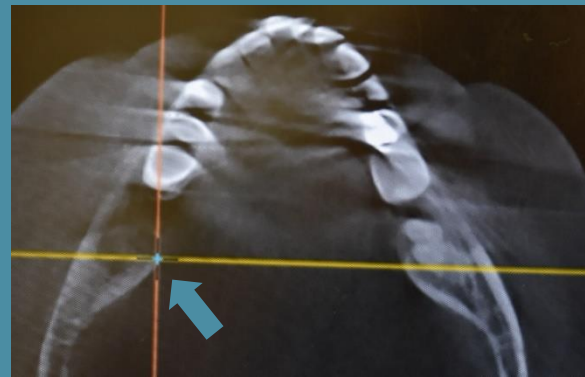Application: Lateral augmentation and vertical augmentation

By: Dr. Gerard Scortecci, D.D.S, Ph.D., Nice, France

Before Extraction and Bone Grafting



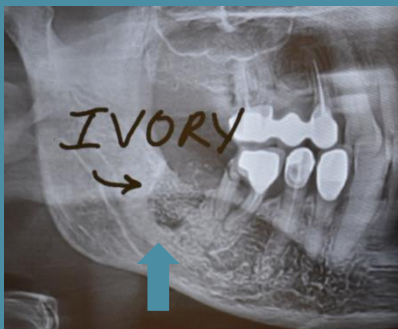
Panoramic scan



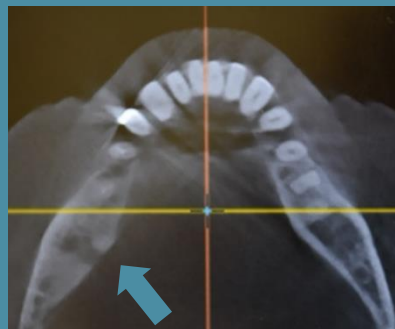CBCT scan: Axial

After Bone Grafting

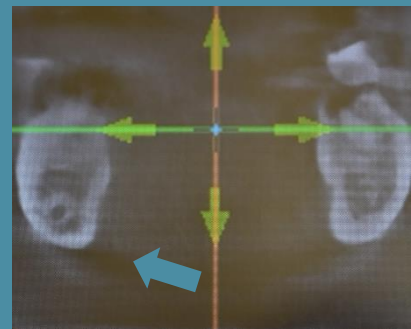
CBCT scans



Just after bone grafting



6 months following bone grafting: Axial and Sagittal planes



"Complete Lingual bone reconstruction with Ivory Dentin Graft" Dr. Gerard Scortecci