

IVORY Graft

Case Report

Patient: Healthy non-smoking male, in his early 60's

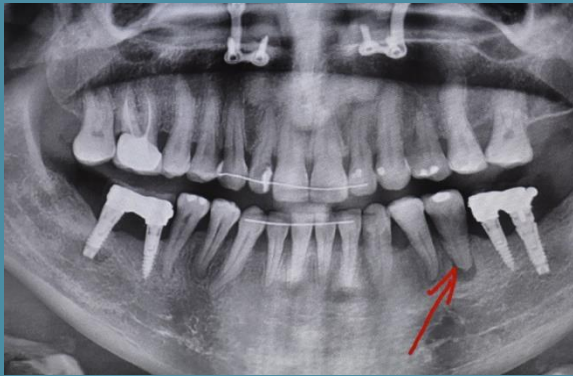Medical condition: Extraction of tooth 35, and apical cyst removal

Graft: Ivory's Dentin Bone Graft (from a syringe), mixed with patient's own blood

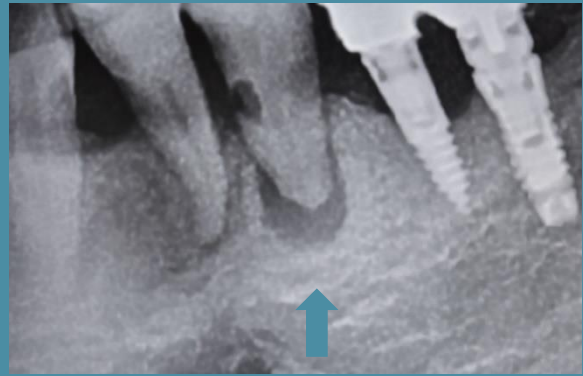
Application: Socket preservation

By: Dr. Gerard Scortecci, D.D.S, Ph.D., Nice, France

Before Extraction and Bone Grafting



Panoramic scan



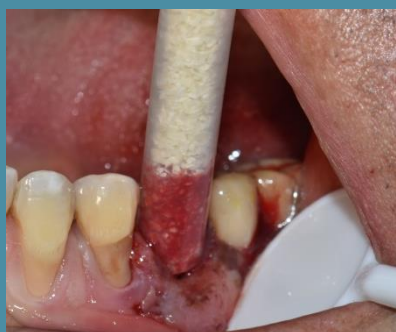Periapical Image

Following Extraction, Mixing Bone Graft with Patient's Own Blood

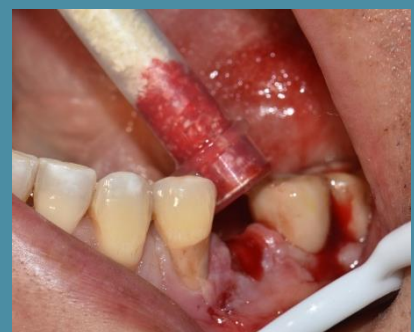Photographs



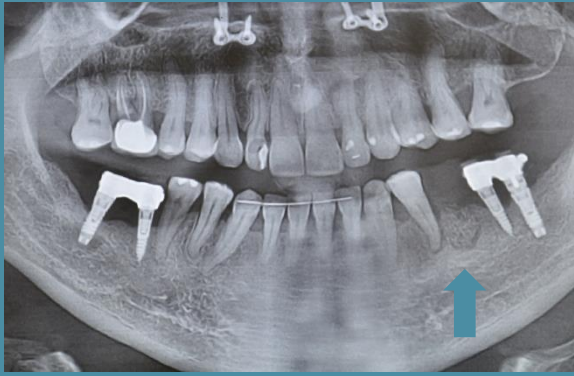Ivory Dentin Graft



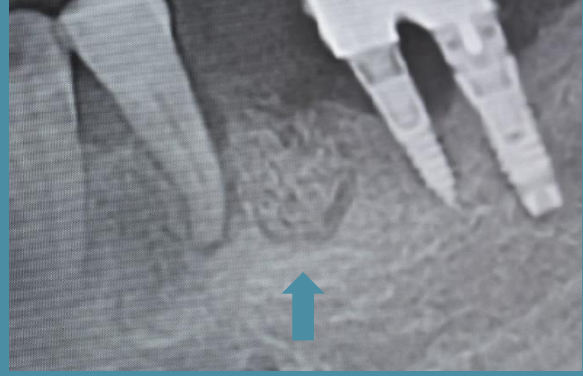Mixing Dentin Graft and Patient's Blood



Just after Bone Grafting

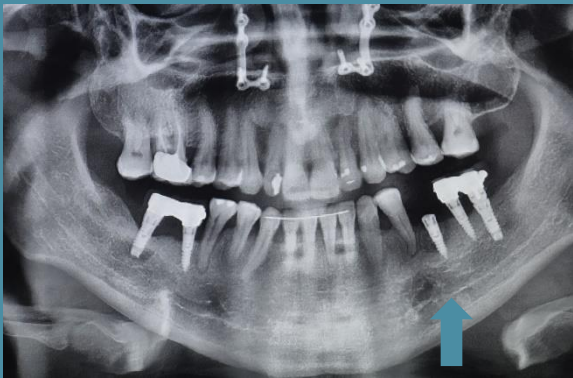


Panoramic scan



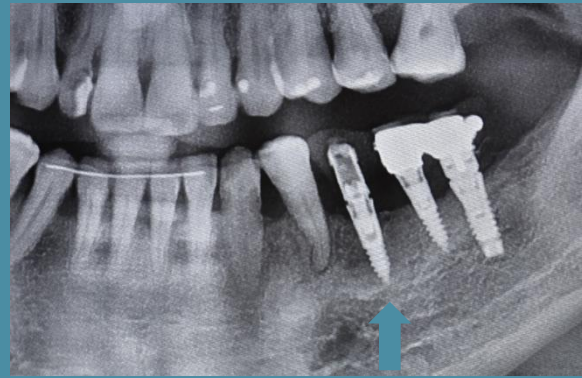
Periapical Image

After Implant Placement



Panoramic scan

2 Years After Bone Grafting



Functional tooth

**"I applied Ivory Dentin Graft in dozens of cases,
and repeatedly resulted zero complications
and high patient satisfaction."**

Dr. Gerard Scortecchi