

# IVORY Graft

## Case Report

**Patient:** Female patient 52 years old

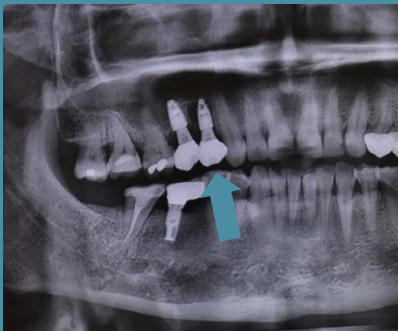
**Medical condition:** Implant apical cyst at tooth 14, requiring extraction

**Graft:** Ivory's Dentin Bone Graft (2 grams)

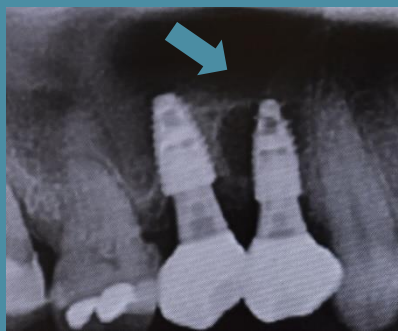
**Application:** Implant extraction and Socket preservation

**By:** Dr. Gerard Scortecci, D.D.S, Ph.D., Nice, France

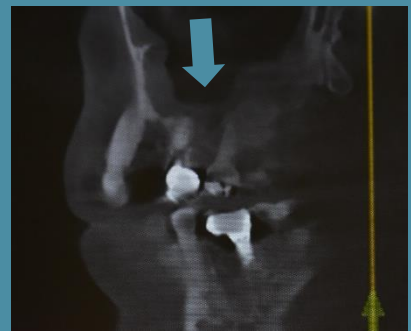### Before and After Implant Extraction



Panoramic scan  
Before implant extraction



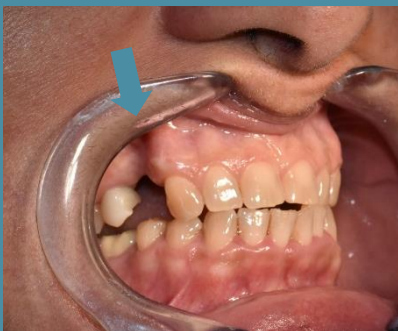Periapical x-ray  
Before implant extraction



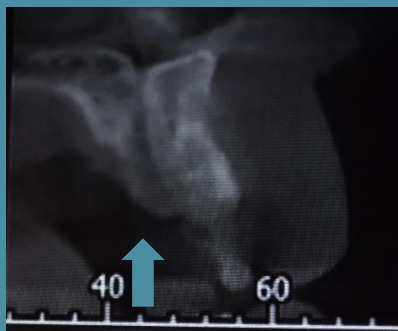
CBCT scan (Sagittal)  
After implant extraction

### 4 Months After Implant Extraction

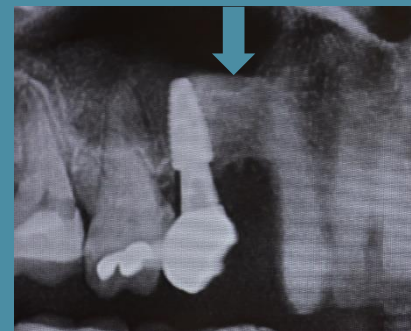
Note the lack of Alveolar bone at tooth 14 area



Photograph



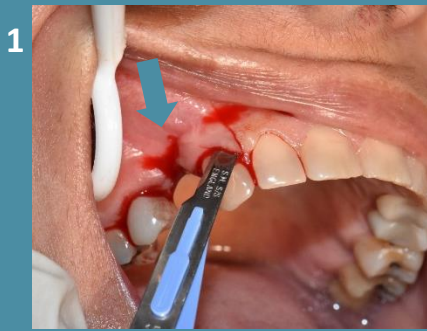CBCT scan (Sagittal)



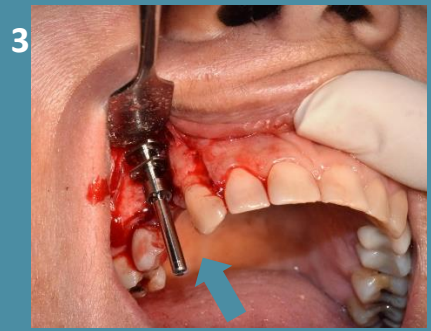
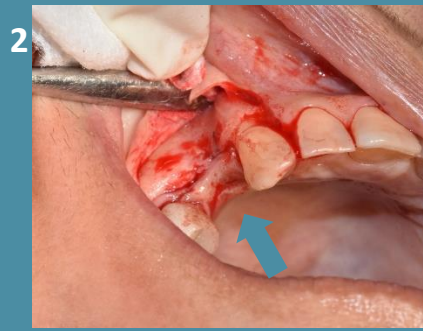Panoramic scan

## 4 Months After Implant Extraction

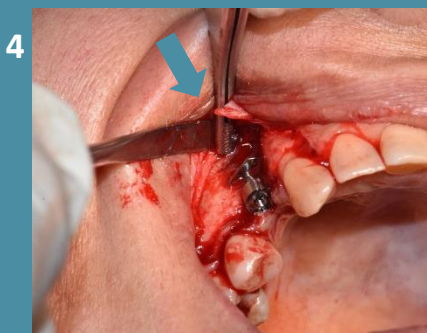Photographs of Implantation and Bone Grafting



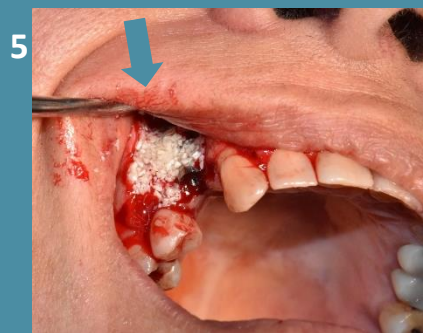Re-entry - opening the flap



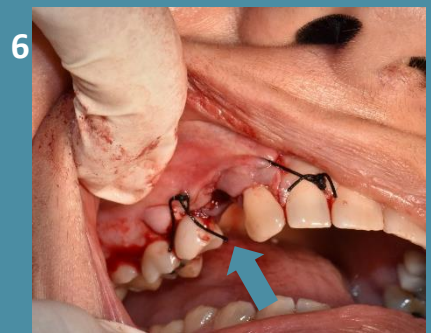Double-disk implant placement



Double-disk implant placement

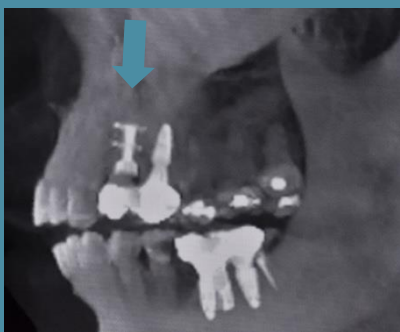

Covering implant with Ivory Graft

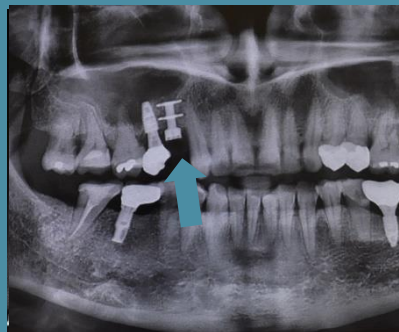


Suturing

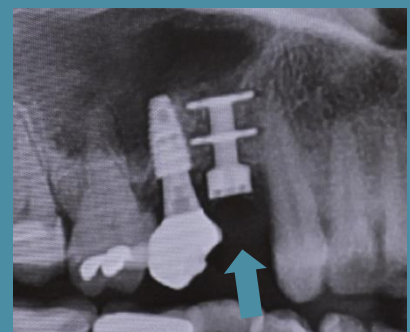
## 6 Months After Implantation



CBCT scan (Sagittal)



Panoramic scan



Periapical x-ray

**“Successful implant replacement despite the lack of bone in implantation area, thanks to stable new bone formation with Ivory Dentin Graft” Dr. Gerard Scortecci**