

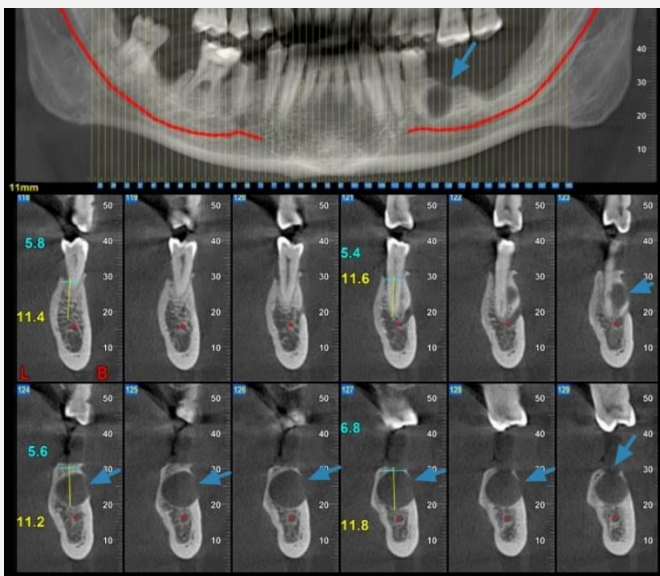
IVORY Graft

Case Report

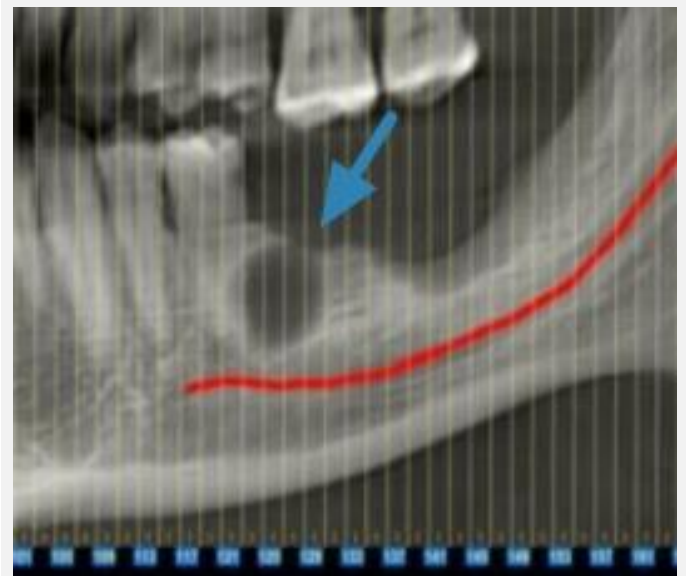
Graft: Ivory's Dentin Bone Graft

Application: Cyst treatment

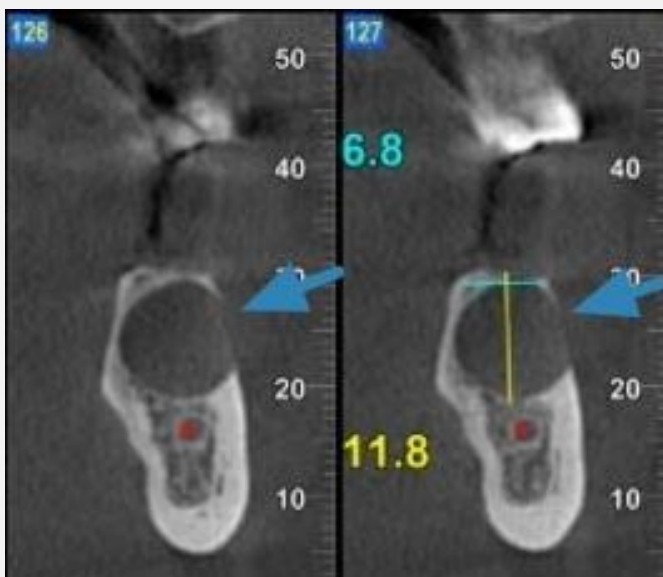
By: Dr. Lari Sapoznikov, DMD, Israel



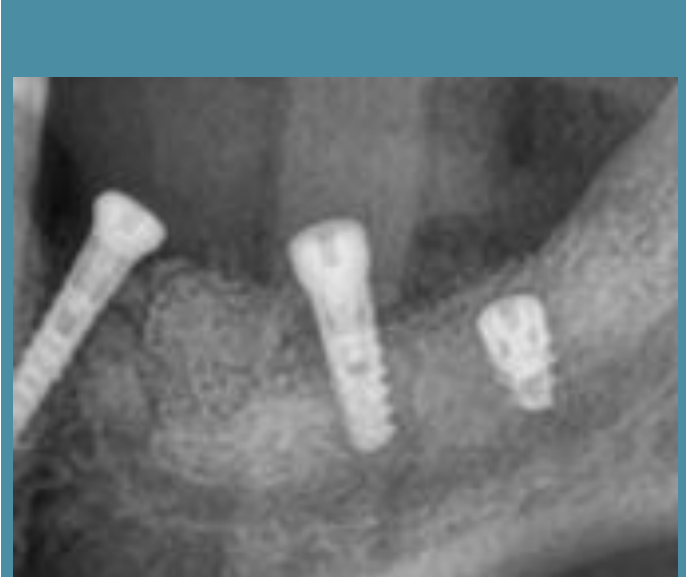CBCT scan
Before bone grafting



CBCT scan
Before bone grafting



CBCT scan
Before bone grafting



CBCT scan
6 months after bone grafting
3 months after implantation